21st Congress of the EAHP
Vienna, Austria - 16-18 March, 2016
Hospital Pharmacists taking the lead – partnerships and technologies

eahp european association of hospital pharmacists

SERVIZO GALEGO de SAÚDE | Xerencia Xestión Integrada A Coruña

IVERMECTIN ENEMA ELABORATION FOR THE TREATMENT OF STRONGYLOIDES HYPERINFECTION

Mondelo García C, García Queiruga M, Feal Cortizas B, Martín Herranz I

Servicio de Farmacia. Instituto de Investigación Biomédica de A Coruña (INIBIC), Complexo Hospitalario Universitario de A Coruña (CHUAC), Sergas. Universidade da Coruña (UDC). As Xubias, 84. 15006 A Coruña, Spain.

Background

❖ Strongyloides stercolaris can produce a life-threatening illness in inmunosuppressed hosts. Treatment options are limited to oral formulations and there is little data on alternative therapies

Purpose

❖ To describe the preparation of ivermectin enema and evaluate its effectiveness in the treatment of Strongyloides hyperinfection.

Material and methods

❖ Bibliographic search in Medline® (key words: ivermectin, rectal, Strongyloides) to know the main characteristics of ivermectin enema: concentration, composition, elaboration method, packaging material, stability and storage conditions.

❖ Review of the electronic medical records and follow-up of the patient during hospitalization.

Results

- Man
- 57 years old
- Brazilian origin

SYMPTOMS
Nauseas, vomits and dizziness

→ **IMAGING TESTS**
Show lesions in his brain
↓
He is operated by **neurosurgery**

→ After a month the patient has haemodynamic instability

→ He is transferred to **INTENSIVE CARE** where he is diagnosed with **Strongyloides hyperinfection** by wet prep of bronchial suction
August 18th 2014

TREATMENT
It is initiated with ivermectin 200 µg/kg/24h by nasogastric tube
August 18th 2014

→ Strongyloides is isolated in feces culture
August 19th 2014

Ivermectin enema 200 µg/kg/24h is added to the treatment
August 22nd 2014

August 25th Strongyloides larvas observed in bronchial suction
August 27th Strongyloides larvas observed in in feces culture

→ **NO movement capacity**

September 3rd and 5 th bronchial suction and feces culture were done
Results were **NEGATIVE**

↓

September 5th Treatment with nasogastric tube and rectal ivermectin **finished**

The elaboration of **ivermectin enema** was required to the pharmacy service because it doesn't exist a commercial presentation appropriate to rectal administration

Elaboration process

Crush ivermectin 12 mg tablets in a mortar until fine powder

→

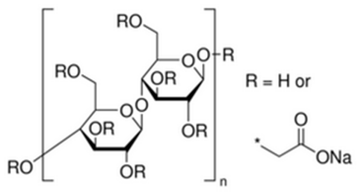

Wet the powder with a small quantity of carboxymethylcellulose 1.5% until homogeneous mixture

→

30 ml

Add small porportions of carboxymethylcellulose until complete 30 ml

Stability: The enema has to be used inmediately

Conclusions

❖ A protocol for the elaboration of Ivermectin enema was stablished. The treatment with rectal ivermectin added to ivermectin oral administration is an effective therapeutic option for the treatment of Strongyloides hyperinfection.

CP 197